



## UTERINE CIRSOID ANEURYSM , MIMICKING OVARIAN CYST; DOPPLER ULTRASOUND AND MDCT FEATURES.

**Dr. Krishna Kumar. M**

Associate professor & HOD, Department of Radiology, DM Wayanad Institute of Medical Sciences,  
Naseera Nagar, Meppadi P.O, Wayanad, Kerala.  
Email: [drmkrishnakumar@gmail.com](mailto:drmkrishnakumar@gmail.com)



**Dr. Krishna Kumar. M**

### ABSTRACT

Uterine arterio-venous malformations (AVM) are rare but potentially life-threatening lesions that should be suspected in women of reproductive age with unexplained vaginal bleeding and in postmenopausal women in whom anechoic structures are detected at ultrasonography (US). Uterine AVM may be acquired or congenital. Acquired uterine AVMs are caused by an iatrogenic event such as curettage, therapeutic abortion & pelvic surgery or as a result of pathological conditions such as, cervical carcinoma, endometrial carcinoma, gestational trophoblastic disease or infection.

Congenital AVMs are the result of abnormal development of primitive vessels that result in connections between pelvic arteries and veins in the uterus without an interconnecting capillary bed.

Color duplex Doppler Ultrasound is valuable in the detection and characterization of many uterine vascular lesions, including arterio-venous malformations (AVMs). Arteriovenous fistulas demonstrate a mosaic pattern representing turbulent flow. Spectral analysis of intralesional arterial flow demonstrates high-velocity flow with a low resistive index, and spectral analysis of intralesional venous flow shows high peak systolic velocities consistent with an arterial flow pattern.

AVM of the uterus may be noted incidentally by Computed Tomography (CT) of the pelvis. Magnetic Resonance Imaging (MRI) is frequently used to confirm and further characterize the sonographic findings of uterine AVM. Catheter angiography and embolization are very effective in defining the vascular anatomy and treating uterine vascular abnormalities respectively.

**Key words;** Cirsoid aneurysm, Color duplex Doppler Ultrasound , Embolization, MDCT, MRI, Uterine AVM .

©KY Publications

### INTRODUCTION:

Uterine arterio-venous malformation [AVM] is a rare condition, with fewer than 100 cases reported in the literature [1]. It is a potentially life-threatening condition, as patients may present with profuse bleeding. ColourDuplex Doppler ultrasound [US] provides a non invasive method for initially diagnosing this rare

condition and confirmation can be made using diagnostic angiography. Conservative management or embolisation is a preferable method of treatment in order to avoid a hysterectomy in patients of child-bearing age.

This case report highlights our experience with a patient having this rare gynaecological condition in our medical center.

#### **MATERIALS AND METHODS:**

##### **Case Report:**

A 36 year old female presenting with menorrhagia and chronic back pain was investigated in our medical centre. Clinical examination was unremarkable. Hemogram showed hypochromic microcytic anemia with hemoglobin of 8 gm%. Pelvic greyscale ultrasonographic examination [Figure 1] showed a lobulated anechoic cystic lesion, measuring about 6x4cm in the right adnexa mimicking ovarian cyst. However enlarged right ovary with functional cyst was seen separate from the cystic lesion.

Color Doppler sonography [Figure 2] demonstrate a mosaic pattern within the cystic lesion representing turbulent flow.

Pulsed Doppler spectral analysis [Figure 3] of intralesional arterial flow demonstrates high-velocity flow with a low resistive index, and spectral analysis of intralesional venous flow shows high peak systolic velocities consistent with an arterial flow pattern.

MDCT Axial, coronal and sagittal [Figure 4] showed a lobulated hypodense lesion in the lower uterine segment filling with contrast in the arterial and venous phase.

3D Volume rendered CT [Figure 5] image clearly depicted the uterine lesion with right feeding uterine arteries and draining veins. An AVM was diagnosed. The diagnosis was confirmed at surgery and successful surgical intervention was done.

#### **RESULTS AND DISCUSSION:**

Uterine AVMs are rare in nonpregnant women and were first described by Dubreil and Loubat in 1926 [2]. Since then, several terms have been used to refer to these lesions, including cavernous hemangioma, cirroid aneurysm, racemose aneurysm, arterio-venous aneurysm, pulsatile angioma, and arterio-venous fistula [2-6].

However, it is a potentially life-threatening disorder in which patients present with vaginal bleeding that may be profuse and cause hemodynamic instability. Thus, it is an important differential to be considered in women of reproductive age with unexplained vaginal bleeding and in post-menopausal women when anechoic structures are identified by US [7].

AVM consists of proliferation of arterial and venous channels with fistula formation and a mixture of capillary-like vessels. The size of these vessels varies considerably, which probably accounts for the variety of descriptive terms found in the literature. Uterine AVMs are generally congenital [7].

Congenital AVMs have multiple vascular connections and tend to invade the surrounding structures (eg, muscle, skin, viscera). They are believed to result from arrested vascular embryologic development.

In contrast, arterio-venous fistulas are usually acquired and typically represent a single artery joining a single vein. They have been reported as a consequence of previous uterine trauma (eg, prior pelvic surgery, curettage), use of intrauterine contraceptive devices, pathologic pregnancy-related events, and previous treatment for gestational trophoblastic disease.

Bleeding is the major presenting symptom in AVMs. Because these malformations are less common after menopause, postmenopausal bleeding is rarely seen.

Congestive heart failure secondary to a vascular steal syndrome is a less common clinical manifestation. Clinical examination may be unremarkable. At vaginal examination, audible bruits and a pulsatile mass may be detected. In patients with a history of unexplained vaginal bleeding, the possibility of a uterine AVM must be considered [7].

Many imaging methods have been used to diagnose pelvic AVMs. Contrast material– enhanced computed tomography, duplex Doppler US, angiography and, more recently, magnetic resonance imaging have proved useful in this setting.

In uterine AVMs, gray-scale US shows a normal-appearing endometrium, whereas the myometrium contains multiple hypoechoic or anechoic spaces [Fig 1]. At color Doppler US, these cystic spaces generate color signals in a mosaic pattern representing turbulent flow [Fig 2] [6]. Spectral analysis of the arterial vessels within the lesion shows high-velocity flow with a low resistive index [approximately 0.51–0.65] [Fig 3]. Spectral analysis of venous flow demonstrates a similar pattern [Fig 3].

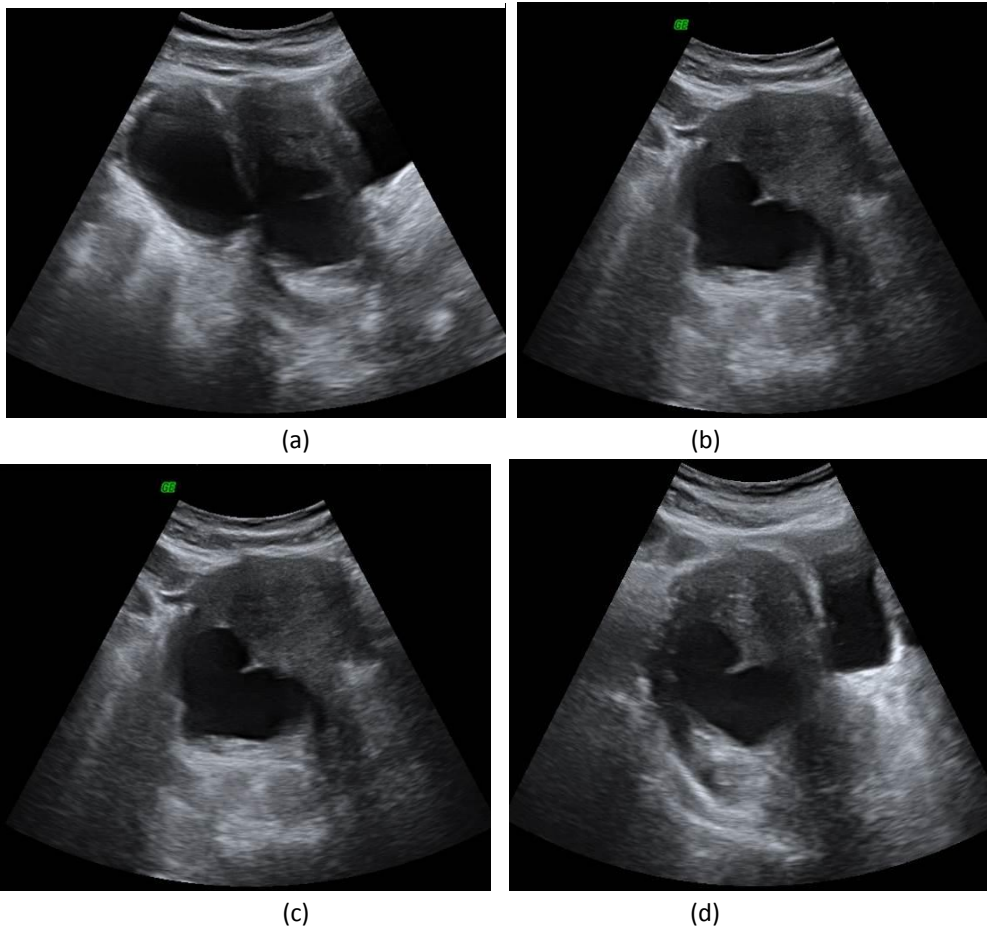
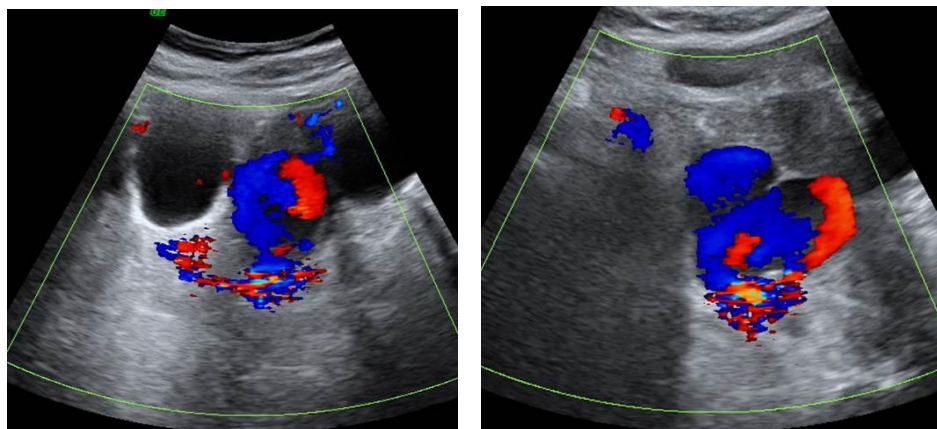


Figure 1a-d. showed a lobulated anechoic cystic lesion measuring about 6x4cm in the right adnexa mimicking ovarian cyst.



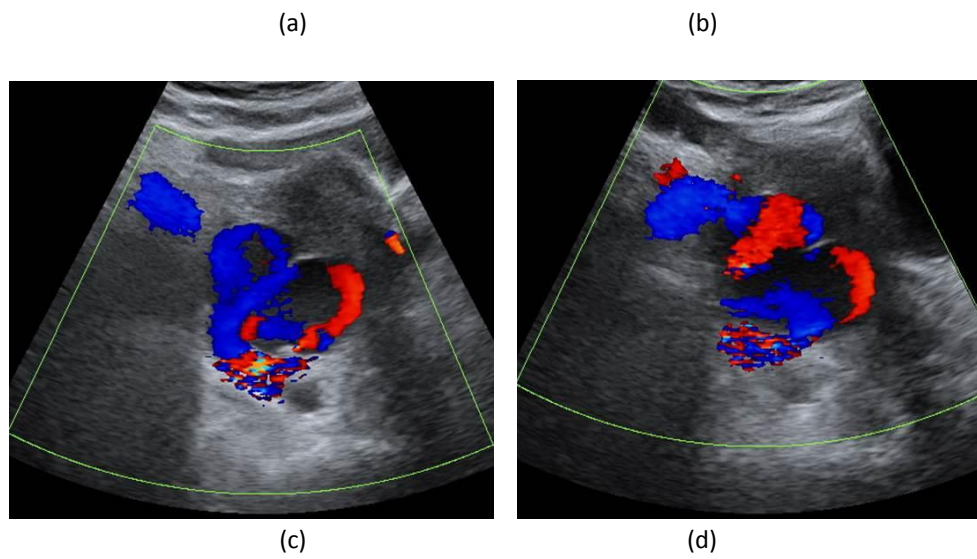


Figure 2a-d. Color Doppler sonography demonstrate a mosaic pattern with intermixing of colours within the cystic lesion representing turbulent flow.

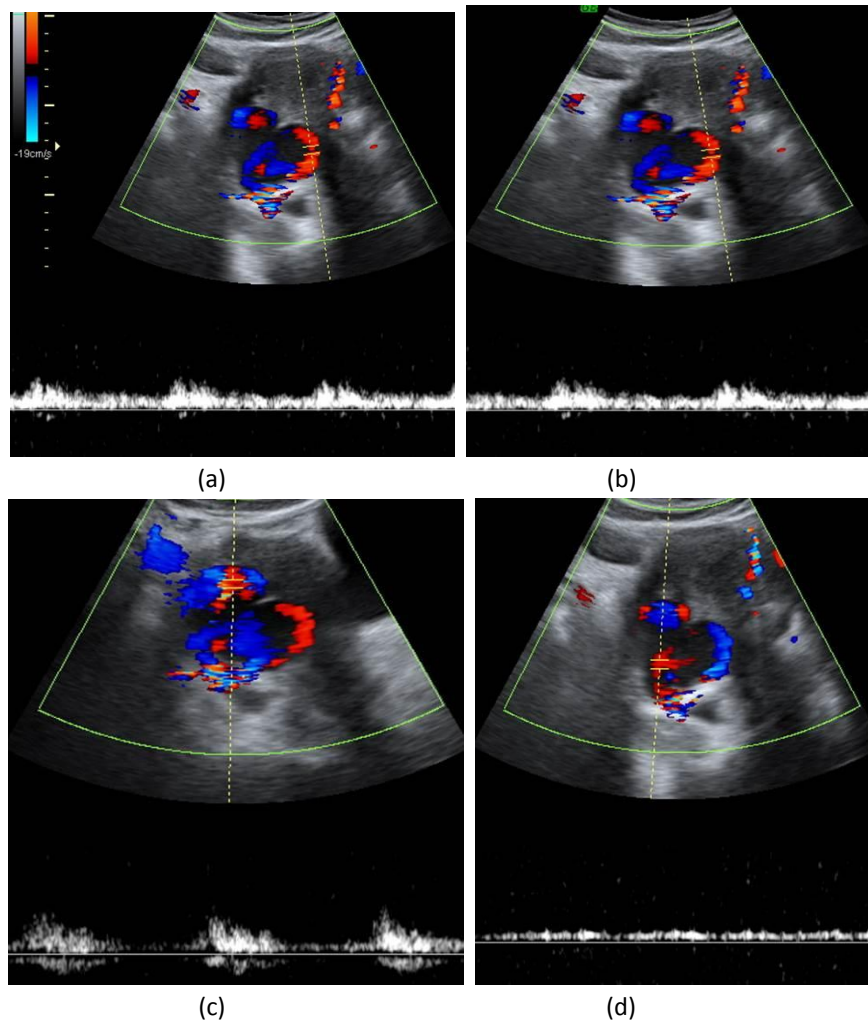


Fig 3a-d. Pulsed Doppler spectral analysis of intralésional arterial flow demonstrates high-velocity flow with a low resistive index, and spectral analysis of intralésional venous flow shows high peak systolic velocities consistent with an arterial flow pattern.

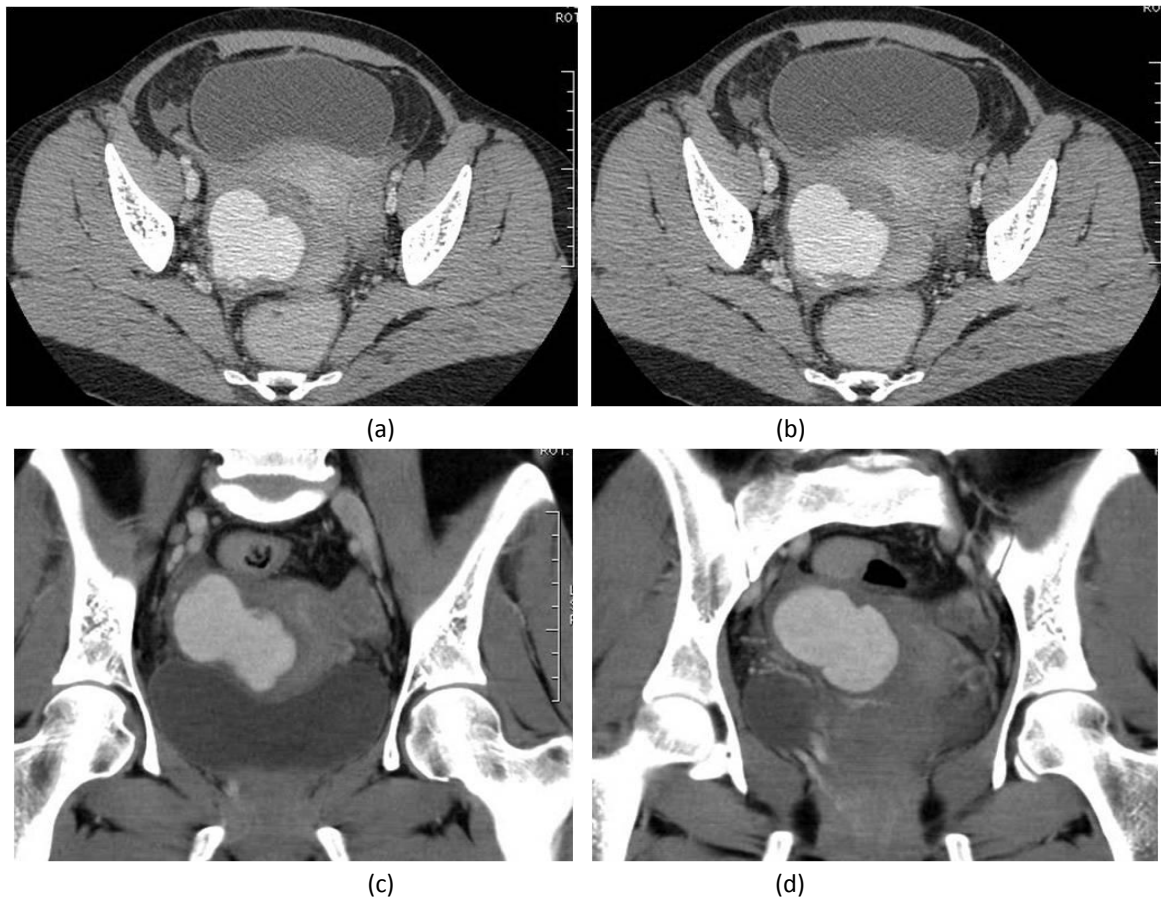
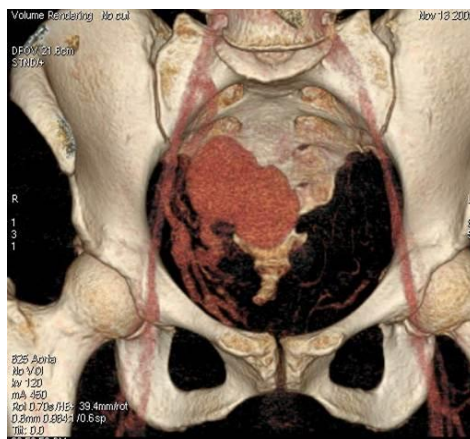


Fig 4a-f . MDCT Axial, coronal and sagittal showed a lobulated hypodense lesion in the lower uterine segment filling with contrast in the arterial and venous phase.



In this case, it is possible that an acquired form of uterine AVM was present in the patient, given the history of uterine trauma such as curettage in the past and caesarean section.

In our study, we found that AVMs of uterus can be diagnosed by colour duplex Doppler sonography. Wiebe and Switzer [8] reported similar findings. Contrast enhanced MDCT with 3D volume rendered images clearly depicted the uterine mass with right feeding uterine arteries and draining veins further confirming the duplex Doppler US findings.

Digital subtraction angiography [DSA] remains the gold standard for the diagnosis of AVM. Findings with DSA include bilateral hypertrophy of uterine arteries that feed a tortuous, hypertrophic arterial mass with large accessory feeding vessels, and early drainage into enlarged hypertrophic veins [9]. However, DSA is rarely performed for diagnosis alone due to its invasive nature and is usually reserved when a patient requires surgical intervention or embolization.

Management of uterine AVM depends on the hemodynamic status, degree of bleeding, patient age, and desire for future fertility. Acute treatment involves stabilizing the patient's hemodynamic status, and stopping blood loss. Large lesions [involving the subendometrial tissue] usually require surgical intervention while others respond to conservative management.

Traditionally, a hysterectomy was the treatment of choice. However, the patient's desire for future pregnancy is an important consideration, as there are now options available to avoid a hysterectomy. In stable patients who have the ability for close follow-up, expectant, and long-term medical management may be appropriate [10].

Since the first description of a successful embolisation treatment for uterine AVM in 1986, it has been commonly used in the emergency setting as well as less urgent circumstances. Various embolic materials have been used, including polyvinyl alcohol, histoacryl [glue], stainless steel coils, detachable balloons, and haemostatic gelatine. Some cases may require repeat embolisation [9].

In addition, because uterine AVM is commonly diagnosed in women of childbearing age, angiographic embolisation has made hysterectomy no longer necessary. Pregnancy following conservative medical management of AVM and even after successful embolisation, although rare has been reported in literature [11-12].

However, hysterectomy remains the treatment of choice in post-menopausal patients or as an emergency treatment in life-threatening situations [13].

This case report highlights the use of Duplex Doppler US and MDCT for diagnosing uterine AVM in a patient of childbearing age who presented with Menorrhagia.

#### **CONCLUSION**

Uterine AVMs are more common than previously thought. Uterine AVMs should be considered as a possibility in cases of refractory intrauterine bleeding. Colour duplex Doppler sonography, contrast enhanced CT or MRI are important for proper assessment of these lesions. The size and site of the lesions probably have a major role in deciding whether the patient needs medical or surgical intervention, however further studies are required to substantiate this hypothesis.

In addition, because uterine AVM is commonly diagnosed in women of childbearing age, angiographic embolisation has made hysterectomy no longer necessary.

#### **REFERENCES:**

- [1]. Hickey M, Fraser I. Clinical Implications of Disturbances of Uterine Vascular Morphology and Function. *BaillieresClinObstetGynaecol*. 2000; **14(6)**:937–951.
- [2]. Dubreil G, Loubat E. Aneurysmecsirsoidedel'uterus. *Ann AnatPathol* 1926; 3:697–718.
- [3]. Gantchev S. Vascular abnormalities of the uterus, concerning a case of diffuse cavernous angiomatosis of the uterus. *Gen DiagnPathol* 1997; 143:71–74.
- [4]. Sugiyama T. Diagnosis of uterine arteriovenous malformation by color and pulsed Doppler ultrasonography. *Ultrasound ObstetGynecol* 1996; 8:359–360.

- [5]. Jain KA, Jeffrey RB, Sommer FG. Gynecologic vascular abnormalities: diagnosis with Doppler US. *Radiology* 1991; 178:549–551.
  - [6]. Abu Musa A, Hata T, Hata K, Kitao M. Pelvic arteriovenous malformation diagnosed by colorflow Doppler imaging. *AJR Am J Roentgenol* 1989; 152:1311–131.
  - [7]. Polat P, Suma S, Kantarcy M, Alper F, Levent A. Colour Doppler Ultrasound in the Evaluation of Uterine Vascular Abnormalities. *Radiographics*. 2002;**22**:47–53.
  - [8]. Wiebe ER, Switzer P. Arteriovenous malformation of uterus associated with medical abortion. *Int J ObstetGynaecol*. 2000;71:155–8.
  - [9]. Grivell R, Reid K, Mellor A. Uterine Arteriovenous Malformations: A review of the Current Literature. *ObstetGynaecol Survey*. 2005;**60(11)**:761–767.
  - [10]. HilwatiHashim, OuzreiahNawawi. Uterine Arteriovenous Malformation . *Malays J Med Sci*. Mar-May 2013; 20(2): 76-80
  - [11]. Chow TWP, Nwosu EC, Gould DA, et al. Pregnancy following successful embolisation of a uterine vascular malformation *Br J Obstet Gynaecol*. 1995; 102: 166–8.
  - [12]. Poppe W, Van Assche FA, Wilms G, et al. Pregnancy after transcatheter embolization of a uterine arteriovenous malformation. *Am J ObstetGynaecol*. 1987; 156: 1179
  - [13]. Delotte J, Chevallier P, Benoit B, Castillon J, Bongain A. Pregnancy after Embolisation Therapy for Uterine Arteriovenous Malformation. *Fertility and Sterility*. 2006; 85(1):228e1–6.
-