



## VARIATIONS OF RECURRENT LARYNGEAL NERVE ORIGIN IN FOETUSES OF II AND III TRIMESTERS

Dr. TERESA RANI.S<sup>\*1</sup>, Dr. B.VIJAYA NIRMALA<sup>2</sup>

<sup>1</sup>Assistant Professor of Anatomy, Siddhartha Medical College, Vijayawada, Andhra Pradesh, Affiliated To Dr. NTR University of Health Sciences, Vijayawada, Andhra Pradesh

<sup>2</sup> Assistant Professor of Anatomy, Guntur Medical College, Guntur, Andhra Pradesh, Affiliated To Dr. NTR University of Health Sciences, Vijayawada, Andhra Pradesh

\*Corresponding Author

e mail: strani2k10@gmail.com



Dr. TERESA RANI.S

### Article Info:

Received: 12/01/2015

Revised on : 20/01/2015

Accepted on: 24/01/2015

### ABSTRACT

Embryologically the spinal nerves are formed due to migration of cells from their original site along with elongation of their nerve fibres. Vagus nerve has an extensive course and distribution than any other cranial nerve, traversing from upper part of the neck, through thorax and enters abdomen and supplying almost all the organs. The origin of Recurrent Laryngeal Nerve on right and left sides differ, which is explained to be due to the development of aorta and its branches from aortic arches and segmental arteries, in the embryonic stage. 100 dead foetuses have been collected and analyzed the origin of RLN variation during II and III trimesters. The origin of RLN was observed in detail as this information will be helpful to paediatric surgeons.

**Key words:** Recurrent Laryngeal Nerve (RLN), dead foetus, II trimester, III trimester

©KY Publications

### INTRODUCTION

All the fibres from cranial portion of the accessory nerve pass through Inferior vagal ganglion without synapsing. Some of the accessory fibres descend in the trunk of vagus, to be distributed to larynx through recurrent laryngeal branch of vagus. RLN is a mixed nerve, carrying motor fibres which supply all the intrinsic muscles of larynx except cricothyroid, sensory fibres supply laryngeal mucosa below the level of vocal folds and trachea and secreto motor fibres supply all the mucous secreting glands present in the mucous membrane.

Right Recurrent Laryngeal Nerve (RRLN) arises on the anterior aspect of vagus nerve, at the level of first part of the subclavian artery i.e., at the inner margin of 1<sup>st</sup> rib. From its origin RRLN curves backwards, below and then posterior to the 1st part of subclavian artery. It then ascends obliquely to lodge in the tracheo-oesophageal groove.

Left Recurrent Laryngeal Nerve (LRLN) arises from the vagus nerve on the left side of arch of aorta in the superior mediastinum of thorax, adjacent to ligamentum arteriosum.

- At its origin, the nerve is situated at the left surface of the arch of aorta.
- It curves the arch of aorta in between the ligamentum arteriosum and left pleura, just above the level of angle of Louis, ascends towards the tracheo-oesophageal groove and later lodges in it.

- c) Left recurrent laryngeal nerve runs posterior to the thoracic duct up till transverse process of 7<sup>th</sup> cervical vertebra.

**Materials and methods:** The study was conducted in the department of Anatomy, Kakatiya Medical College, Warangal. 100 dead II and III trimester fetuses of have been collected from Chanda Kanthiah Memorial hospital, Warangal, Government Maternity Hospital, Hanamkonda and few private nursing homes in Warangal. All the specimens were either aborted, stillborn or premature deliveries resulting in neonatal death.

Chemicals used are Formalin for preservation, Glycerine to keep the tissues soft and Copper Sulphate as antifungal agent.

Specimens were collected within 10 hours after death. Depending on the size, the fetuses were embalmed with 10% formalin to expose the vagus nerve and RLN a systematic dissection procedure has been adopted.

The following parameters have been included:

- A. Length of foetus:- length of all the foetuses have been measured in centimeters i.e. the crown rump length, to calculate approximate age of foetuses in weeks.
- B. Weight of fetus:-The weight of all fetuses along with 5cm-6cm of umbilical cord have been taken in grams with the help of a simple balance.
- C. Cranial diameters: Biparietal diameters i.e., distance between two parietal eminences of all the specimens were measured with vernier calipers.

A detailed dissection was carried out on each specimen, on right and left sides. The RLN was traced on both sides from its origin till its termination into the larynx.

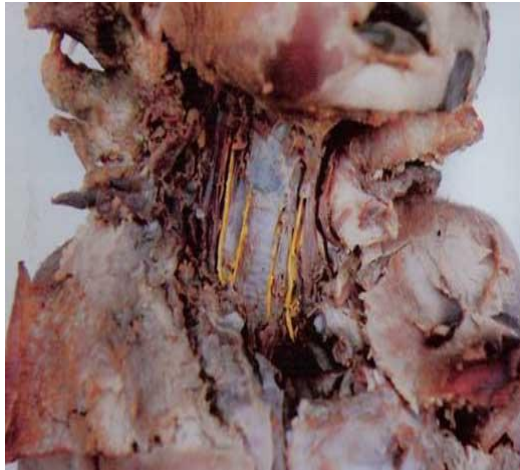The dissected specimens were blotted with blotting paper and were painted with fabric paint. Lemon yellow colour is used for RLN and its branches. The specimens thus painted were photographed.

## RESULTS

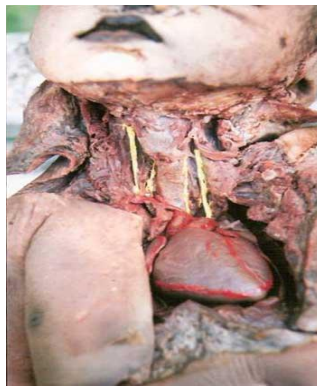
For this study 100 dead fetuses of II and III trimester were selected to observe the origin of RLN on both sides. In all the fetuses of II trimester the origin of RRLN was at the level of 7<sup>th</sup> cervical vertebra and anterior to the subclavian artery. We have observed one variation in 2 foetuses of III trimester. Such a variation is named as Non Recurrent Laryngeal Nerve or cervical formation of the nerve. In II & III trimester fetuses the formation of the LRLN was anterior to the arch of aorta in the superior mediastinum close to the ductus arteriosus.

## DISCUSSION

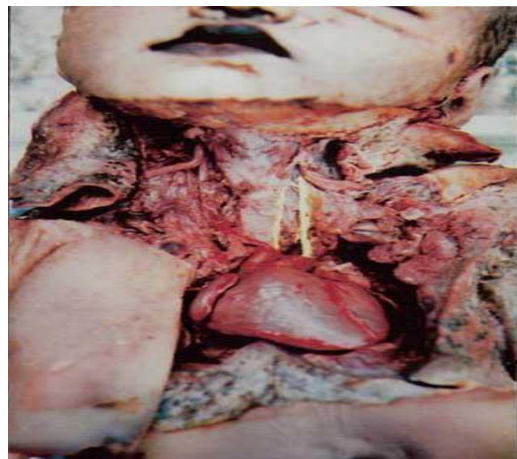
Larynx consists of a skeleton of cartilages, inter-articulated by synovial joints and membrane like ligamentous attachments. Movements of these cartilages are by contraction of the muscles, majority of which are intrinsic. Inner surface of the Larynx is covered by mucous membrane, which forms firm antero-posterior folds an upper vestibular and a lower vocal folds. Of the two folds only vocal folds has extension of muscle fibre of thyroarytenoid named vocalis. The RLN as the name suggests has a recurrent course especially extensive on the left side. The explanation for such extensive recurrent course has been attributed to the development of arch of aorta from aortic arches. Any injury to RLN in cervical surgical procedures and on the left side any surgery extending up to the superior mediastinum will result in changes of voice like hoarseness or total loss of voice, which is usually permanent and rarely temporary. The RRLN is normally formed on the anterior aspect of 1<sup>st</sup> part of right subclavian artery. The variation of origin of RLN was observed to be occurring in 0.2 to 1% of the cases. In the present study, 2 fetuses of III trimester group consisting of 62 fetuses, were observed to have cervical origin, 3.2%. RRLN was found to arise at the level of thyroid cartilage.



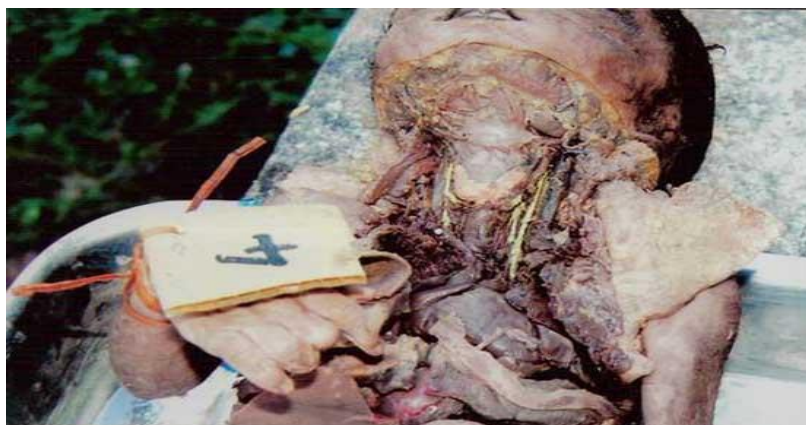DISSECTION OF VAGUS NERVE AND RLN ON RIGHT AND LEFT SIDES (COLOURED YELLOW)



DISSECTION SHOWING RLN ON RIGHT AND LEFT SIDES (COLOURED YELLOW)



TRIMESTER –III SHOWING DISSECTION OF RLN ON LEFT SIDE ORIGIN AT THE LEVEL OF ARCH OF AORTA



DISSECTION OF NON RLN ON RIGHT SIDE-NORMAL ORIGIN O FRLN ON LEFT SIDE

Fetuses were grouped as II and III trimester based on CR length. Out of 100 randomly collected fetuses 38 were grouped as II trimester and 62 as III trimester of which 73 were male fetuses and 27 were female fetuses.

S.No.	Material	Total No.	Male	Female
1	II trimester fetuses	38	24	14
2	III trimester fetuses	62	49	13

#### ORIGIN OF RLN

	II trimester		III trimester	
Normal	38	38	60	62
Variation	-	-	2	-

Variation	III trimester	
	R	L
Winds round the 1 <sup>st</sup> part of sub clavian artery	60	62
Cervical formation i.e., Non-recurrent laryngeal nerve	2	0

#### CONCLUSION

A detailed study RLN has been considered as all intrinsic muscle of Larynx including vocalis & mucous membrane is supplied by the recurrent laryngeal nerve. Therefore any irritation due to infection or pressure due to tumours or injury to the RLN during cervical surgery will lead to change of voice. The origin or entry of RLN into larynx differs on right and left sides which is an important information essential for all surgeons. Anomalies can be detected in utero by Ultrasonography and MRI which enables surgeons to assess the exact extent of anomaly and plan for Medical Termination of Pregnancy or neonatal surgery.

#### REFERENCES

- [1]. Andrews Vesalius Gray's Anatomy 36<sup>th</sup> Edition 810, 1514-64.
- [2]. Ardito G, Reelli L, D Alatrill, Lerro V, Guidi MI, Ardito F "Revisited anatomy of the recurrent laryngeal nerve" Am J Surg 187(2): 249-53 Feb 2004.
- [3]. Aytac B, Karamercana "Recurrent laryngeal nerve injury and preservation in thyroidectomy". Saudi Med J 26(11): 1746-9, Nov 2005.

- [4]. Bachhuber, C.A. *"complications of thyroid surgery: Anatomy of the recurrent laryngeal nerve: middle thyroid vein and inferior thyroid artery"*. AM.J. Surg. N.s.60:96, 1943.
- [5]. Balanzoni. S, Actini R, Pasil, Fusslf. *"Prevention of laryngeal nerve lesion in thyroid surgery.."* Minerva chir, 49(4):299-302, Apr, 1994.
- [6]. Bassam Abbound Md and Romy Aouad Md. *"Non-recurrent inferior laryngeal nerve in thyroid surgery. Report of 3 cases and review of the literature"*. Journal of laryngology & Otology (118) 139-142 2004.
- [7]. Berlin, DD., and Lahey, F.H. *"Dissections of the recurrent and superior laryngeal nerves: the Relation of the recurrent to the inferior thyroid artery and the relation of the superior or abductor paralysis, Surg., Gynec. Obst. 49:102, 1929.*
- [8]. Bernardo Almeida Campos, Paulo Roberto Ferreira Henriques. *"Relationship between the recurrent laryngeal nerve and the inferior thyroid artery. A study in corpses"* Revista do Hospital das clinics Vol 55 No.6 195-200 Nov/Dec 2000.
- [9]. Brauek Hoffm, Wails G, Brauck Hoffk, Thanh PN, Thomusch O, Dralle H. *"Identification of non recurrent inferior laryngeal nerve using intra operative neuro stimulation"*. Langenbecks Arch surg 386(7): 482-7 Jan 2002.
- [10]. C.Avisse, C.Marcus, J.F.Delattre, J.P.Carlliez. *" Right non-recurrent inferior laryngeal nerve and arterial lusoria the diagnostic and therapeutic application of an anatomical anomaly. Review of 17 cases."* Surgical and Radiological anatomy vol 20.(3) 227-232,1998.
- [11]. Damrose EJ, Huang RY, Ye M, Berke GS, Sercarz JA. *"Surgical anatomy of the recurrent laryngeal nerve: implications for laryngeal reinnervation"*. Ann Rhinol Laryngol 112(5): 434-8 May 2003.
- [12]. DVORAK J, KUBINS, HOF MANN, DYRED. *"Non Recurrent laryngeal nerve"* Rozhl Chir 83(2):62-6 Feb 2004.
- [13]. DVORAK J, KUBLIN S, SCHUSTER J, HLAVATY T. *"Detection, identification and visualization of the recurrent laryngeal nerve in thyroidectomy – still a surgical dilemma"*. Rozhl chir 81(6): 282-9 Jun 2002.
- [14]. FLAMENT JB, DELATTRE JF, PALOT JP. *"Anatomic pitfalls of recurrent laryngeal nerve dissection."* J.chir (paris); 120(5): 329-33, May 1983.
-